

# Oral Cancer

Prevention and patient management



LEADING THE WORLD TO OPTIMAL ORAL HEALTH

# What is oral cancer?

Oral cancer is a type of head and neck cancer and is any cancerous tissue growth located in the oral cavity<sup>1</sup>. Head and neck cancers are the sixth most common form of cancer globally<sup>2</sup>, and around 500,000 new cases of oral and oropharyngeal cancers are diagnosed annually, three-quarters of which occur in the developing world<sup>3,4</sup>.

Ninety percent of oral and pharyngeal cancer cases are classified as squamous cell carcinoma<sup>5</sup>. Forty percent of head and neck cancers occur in the oral cavity, 15% in the pharynx, and 25% in the larynx, with the remaining tumours occurring at other sites (salivary glands and thyroid)<sup>6</sup>.

Oral cancer is a cancer of the upper aerodigestive tract. It includes cancer of the lip, the labial and buccal mucosa, the anterior two thirds of the tongue, the retromolar pad, the floor of the mouth, the gingiva and the hard palate (see *Annex 1*). It refers to all malignant tumours, including carcinomas arising from the epithelium and sarcomas arising from submucosal regions such as non-epithelial tissues. Carcinomas arise not only from oral mucosa, but also salivary glands and metastatic tumours of other epithelial organs. Malignant lymphoma, nerve-related malignant tumours arising from submucosal regions, are also oral cancer.

The oropharynx, nasopharynx and hypopharynx are excluded from this guideline, as these sites are not easily examined in the dental practice. Sub-sites differ by major risk factor and have variable disease progression<sup>7</sup>.

Up to 70% of oral cancers are preceded by premalignant oral lesions, such as persistent red or white patches in the mouth.

This guideline focuses on the most common sites of oral cancer: the tongue, the insides of the cheeks and the floor of the mouth.

The curability rate of lip and oral cavity cancers varies depending on stage and specific site. Most patients present with early cancers of the lower lip, whose cure rates reach 90% to 100% through surgery or radiation therapy<sup>8</sup>. Oral potentially malignant disorders (OPMD) often precede squamous cell carcinoma



(see *Annex 2*). Early detection of OPMDs can reduce malignant transformation and improve survival rates for oral cancer. Missed opportunities for early diagnosis and treatment, however, result in significant morbidity and mortality worldwide: the five-year survival rate for advanced stage oral and pharyngeal cancer amounts to less than 63%<sup>9,10</sup>.

Survival rates for oral cancer can be improved through early detection<sup>11</sup>. It is therefore essential that oral health professionals (OHPs) such as dentists, dental hygienists (DHs), dental therapists (DTs), and oral health therapists (OHTs) understand the importance of conducting a thorough oral screening examination for malignant and potentially malignant lesions as part of their routine clinical assessments, even in younger populations considered at lower risk for oral cancer. A recent effectiveness review of oral cancer screening has demonstrated conventional oral examination to be a feasible and satisfactory occasion for opportunistic screening in dental settings, with sensitivity and specificity similar to breast and cervical cancer screening programmes. Several studies have assessed dentists' knowledge, attitudes and practices regarding oral cancer. However, few studies include DHs, DTs, and OHTs, meaning that clinical screening practices for oral cancer in the broader dental team remain largely unknown<sup>10</sup>. FDI World Dental Federation and numerous national dental associations proactively encourage OHPs to incorporate oral mucosal examinations as part of routine assessment<sup>12</sup>.

This guideline focuses on oral cancer, which dentists can detect by observing the oral mucosa, as it is both superficial and accessible. The main objectives of this guideline and chairside guide are to:

- ▶ provide OHPs and patients with concise, yet comprehensive, information about oral cancer prevention, risk factors and management;
- ▶ guide clinical examination and diagnosis through a decision tree.

# Risk factors



Oral cancer is among the ten most common cancers but can largely be prevented by reducing exposure to risk factors

## Main risk factors


Consult  
Chairside  
Guide

Oral carcinogenesis is a complex, multi-step process that involves both environmental risk factors and genetic factors. It results from an accumulation of both genetic and epigenetic alterations in oncogenes and/or tumour suppressor genes, which occurs when epithelial cells are affected by various genetic alterations. Tobacco, alcohol and the HPV virus induce such genetic alterations (including key disorders such as epidermal growth factor receptor, TP53, NOTCH1, Cyclin D1, etc.) that trigger transformation of stromal cells, immune suppression, and chronic inflammation<sup>13</sup>. The combination of tobacco and/or alcohol risk factors with certain gene polymorphisms may increase oral cancer susceptibility.

### Tobacco and alcohol

Tobacco products and alcohol consumption are the two established independent risk factors for oral cancer<sup>10</sup> and OPMDs (see *Figure 2*). Most cases of oral cancer are linked to tobacco, heavy alcohol use, or the combined use of both substances, with the latter posing a much greater risk than the use of either substance alone.

**Figure 1** Types of tobacco use



SOURCE *The Challenge of Oral Disease – A call for global action* by FDI World Dental Federation

**Figure 2** Oral cancer facts

Facts about oral cancer	Risk factors	Profile of those at highest risk
<p>The average <b>5-year survival rate</b> of patients with oral cancer is about <b>50%</b>.</p> <p><b>95%</b> About <b>95% of all oral cancers</b> occur in persons over <b>40</b> years of age.</p> <p>The average age at the time of diagnosis is about <b>60</b>.</p>	<p><b>Cigarette smoking</b> is the most common form of tobacco use, but all forms of tobacco are linked with increased risk of oral cancer: <b>regular use of pipes, cigars, waterpipes</b>, as well as all forms of <b>smokeless tobacco</b> (snus, chewing tobacco, etc.).</p> <p>All three forms of <b>alcohol</b> (beer, spirits and wine) have been associated with oral cancer, although <b>spirits and beer</b> have a higher associated risk.</p>	<p>A typical <b>high-risk profile</b> for oral cancer is a <b>man</b>, over age <b>40</b>, who uses <b>tobacco</b> and/or is a heavy user of <b>alcohol</b>.</p> <p>However, the <b>male–female ratio</b> has <b>dropped</b> from 6 to 1 in 1950 to about 2 to 1 at present.</p>

SOURCE *The Challenge of Oral Disease – A call for global action* by FDI World Dental Federation

Tobacco products include any type of smoking tobacco and smokeless tobacco (see Figure 1). Altogether, tobacco causes 90% of oral cancer, and people who drink three to four alcoholic beverages per day have double the oral cancer risk of non-drinkers. Individuals who both smoke and drink have a 35-fold increase in oral cancer risk compared to individuals who never drink or smoke<sup>14</sup>. Reducing tobacco and alcohol consumption can therefore significantly contribute to preventing oral cancer.

## Other risk factors



Although not as significant as major risk factors, other risks factors can trigger oral and/or lip cancer:

HPV	UV sun exposure	Chronic or repeated traumatic factors	Environmental and infectious factors
HPV oral infection increases the risk of oropharyngeal cancer by about 15 times <sup>14</sup> .	UV exposure is a lip cancer risk factor <sup>15</sup> .	Chronic or repeated traumatic factors may promote the transformation of the epithelial cells <sup>14</sup> .	Poor oral hygiene, chronic candidiasis, herpes virus infections and immunosuppressive conditions, e.g. HIV, Fanconi syndrome, may trigger the development of oral malignancy, but evidence is currently weak <sup>16</sup> .

# Prevention of oral cancer

Dentists play an important role in the early detection of oral cancer. In particular, performing oral screening and early diagnosis increases the opportunities to detect the disease in its early stages. In addition, as part of a multi-disciplinary team, dentists play an active role in the different steps that must be taken to prepare patients for oral cancer treatment<sup>1</sup>.

## Oral screening

Consult  
Chairside  
Guide

Only 30% of oral and pharyngeal cancers are identified at an early stage, while 50% are diagnosed at an advanced stage of metastasis (stage III or IV). This is largely due to late presentation, delayed diagnosis, and lack of clear referral pathways between dentists and medical doctors. **Oral cancer screening** must therefore be an essential component of the routine head and neck examination conducted in the primary dental care setting<sup>17–21</sup>.

The primary screening test for oral cancer is a systematic clinical examination of the oral cavity. According to the World Health Organization and the National Institute of Dental and Craniofacial Research, an oral cancer screening examination should include a visual inspection of the face, neck, lips, labial mucosa, buccal mucosa, gingiva, floor of the mouth, tongue, and palate. Mouth mirrors can help visualize all surfaces. The examination also includes **palpating** the regional lymph nodes, tongue, and floor of the mouth. Any abnormality that lasts for more than two weeks should be re-evaluated and referred for **biopsy**<sup>22</sup>.

## Early diagnosis

Consult  
Chairside  
Guide

Early diagnosis is critically important to decrease oral cancer mortality. Most oral cancers develop in areas that can be seen and/or palpated, meaning that early detection should be possible<sup>23</sup>. Key signs are **ulceration, induration, infiltration, bleeding, and nodes**<sup>17</sup>.

Unfortunately, patients are most often identified after the development of symptoms associated with advanced stages of the disease, such as discomfort, dysphagia, otalgia, odynophagia, limited movement of the tongue, limited ability to open the mouth, cervical and submandibular nodes, weight loss and loss of sensory function, especially when the lesion is unilateral.

In contrast, some cancers may be asymptomatic, which further contributes to late diagnosis. Opportunistic oral cancer screening examinations conducted by OHPs therefore remain an important means for early identification and diagnosis.

In early stages, the lesion may be flat or elevated and may be minimally palpable or indurated. Diagnosis is based on clinical examination and biopsy, which is the gold standard procedure. Biopsy should be conducted between sound and pathologic tissues to the depth of the basal layer.

Positive diagnosis:

- ▶ Pre-malignant disorders: leukoplakia, erythroplakia, Lichen planus (see Annex 2)
- ▶ Oral cancer: oral intra-epithelial neo-plasia, in-situ carcinoma, micro-invasive or invasive carcinoma

# Oral cancer patient management

Consult  
Chairside  
Guide

The management of patients with oral cancer is complex. Manifestations of cancer therapy may include infections, mucositis and oral ulceration, xerostomia, bleeding, pain, osteoradionecrosis, taste loss, trismus, and caries. These require prevention and management.

Treatment strategies vary based on the stage of oral cancer at the time of diagnosis. Depending on the stage, treatment may include surgery and/or radiotherapy, leading to a high probability of long-term survival but often with considerable morbidity<sup>24</sup>. Chemotherapy, including targeted therapy, may be combined with radiation in initial treatment or used to treat recurrent cancer. Immunotherapy is a newer option for advanced or recurrent cancer<sup>25</sup>. The choice of treatment also depends on the comorbidities presented by the patient and his/her nutritional status, ability to tolerate treatment, and wishes to undergo therapy. Multidisciplinary treatment is crucial to improve the oncologic results and minimize the impact on function and quality of life.

## Before treatment

Before treatment is initiated, it is recommended that dentists perform a systematic dental assessment and establish an oral care programme to improve treatment compliance by decreasing infection risk. Upon diagnosis, the majority of patients present associated dental pathologies (caries, periodontal disease). Dentists should conduct oral rehabilitation, non-invasive treatment, fluoride dental tray, and maxillofacial prosthesis as appropriate. In addition, radiotherapy (with or without chemotherapy) often induces oral complications, and surgical treatment frequently requires bone resections with dental extractions. Clinical and radiological examination (panoramic) should be performed to repair and remove infectious dental foci. This involves the elimination of dental caries (endodontic management and restorative treatment) and extraction of at-risk teeth with primary wound closure 7 to 10 days before initiation of radiotherapy to minimize the risk of osteoradionecrosis associated with post-radiation dental extractions and elimination of all causes of mucosal trauma<sup>15</sup>.

Depending on the irradiated field, provision should be made for definitive dental fluoridation trays. An oral care programme which includes oral health instruction (tooth cleaning by toothbrush, interdental brush, and dental floss, followed by gargling three times per day), removal of dental calculus (scaling), professional mechanical tooth cleaning, removal of tongue coating with a toothbrush, and denture cleaning should be established.

## During treatment

Dentists should minimize the side effects of radiotherapy and recommend a basic oral self-care programme, which is a combination of toothbrushing, flossing, and rinsing to improve treatment compliance by decreasing infection risk as follows:

- ▶ Post-radiotherapy mucositis: local antiseptic, anesthetic gel use, non-alcoholic alkaline rinsing, more than one-time mouth rinses to maintain oral hygiene;

- ▶ Caries: brush twice-daily with a soft toothbrush and with fluoride toothpaste between 2800ppm and 5000ppm and/or application of fluoride dental tray;
- ▶ Xerostomia: sugar-free chewing gum and salivary substitutes.

## After treatment

- ▶ Specific attention should be given to the healing process and possible recurrence of oral cancer.
- ▶ Follow-up with recall should be done at least twice per year and adapted as required.
- ▶ Any traumatic dental procedures following radiotherapy should be performed under antibiotic cover.
- ▶ Non-traumatic prosthetics for rehabilitation should be performed within 6 to 12 months.

### Partner

This publication was made possible through an unrestricted educational grant from Sunstar.

### Find out more

Quickly access the project page by scanning the following QR code using your mobile phone camera



### References

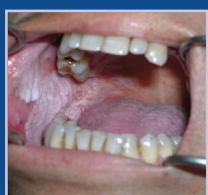1. Werning JW (ed). *Oral Cancer: Diagnosis, Management, and Rehabilitation*. 1st edition. New York: Thieme, 2007.
2. Manuscript 393 - abstract | Rambam Maimonides Medical Journal, <https://www.rmmj.org.il/issues/21/Articles/393> (accessed 23 March 2018).
3. Radhakrishnan R, Shrestha B, Bajracharya D. Oral Cancer - An Overview. *Oral Cancer*. Epub ahead of print 2012. DOI: 10.5772/30399.
4. Chowdhury RM, Singh G, Joshi A, et al. Autophagy and oral cancers: A short review. *J Stomatol Oral Maxillofac Surg* 2018; 119: 37–39.
5. Olson CM, Burda BU, Beil T, et al. *Screening for Oral Cancer: A Targeted Evidence Update for the U.S. Preventive Services Task Force*. Rockville (MD): Agency for Healthcare Research and Quality (US), <http://www.ncbi.nlm.nih.gov/books/NBK132472/> (2013, accessed 23 March 2018).
6. A PhD student of Centre of Doctoral study in health science-Doctoral training in genetics and molecular pathology-Faculty of Medicine and Pharmacy of Casablanca-Hassan IUniversity of Casablanca.Morocco., Sm B, C R, et al. EPIDEMIOLOGICAL PROFILE OF ORAL CANCER IN CHU IBN ROCHD - CASABLANCA - MOROCCO: ABOUT 83 CASES. *Int J Adv Res* 2017; 5: 2218–2223.
7. fdi-oral-cancer-2008.pdf, <https://orlandoms.files.wordpress.com/2011/02/fdi-oral-cancer-2008.pdf> (accessed 23 March 2018).
8. PDQ Adult Treatment Editorial Board. Lip and Oral Cavity Cancer Treatment (Adult) (PDQ®): Health Professional Version. 2018 Feb 8. In: PDQ Cancer Information Summaries [Internet]. Bethesda (MD): National Cancer Institute (US); 2002-. Lip and Oral Cavity Cancer Treatment (PDQ®).
9. Marcazzan S, Varoni EM, Blanco E, et al. Nanomedicine, an emerging therapeutic strategy for oral cancer therapy. *Oral Oncol* 2018; 76: 1–7.
10. Mariño R, Haresaku S, McGrath R, et al. Oral cancer screening practices of oral health professionals in Australia. *BMC Oral Health*; 17. Epub ahead of print December 2017. DOI: 10.1186/s12903-017-0439-5.
11. complete\_oh\_atlas.pdf, [https://www.fdiworlddental.org/sites/default/files/media/documents/complete\\_oh\\_atlas.pdf](https://www.fdiworlddental.org/sites/default/files/media/documents/complete_oh_atlas.pdf) (accessed 26 March 2018).
12. Thail B. Oral Cancer. *FDI World Dental Federation*, <https://www.fdiworlddental.org/resources/policy-statements-and-resolutions/oral-cancer> (2017, accessed 20 June 2018).
13. Curry JM, Sprandio J, Cognetti D, et al. Tumor microenvironment in head and neck squamous cell carcinoma. *Semin Oncol* 2014; 41: 217–234.
14. Screening PDQ, Board PE. Oral Cavity and Oropharyngeal Cancer Prevention (PDQ®).
15. Osterlind A. Cancer and UV-radiation. *Pharmacol Toxicol* 1993; 72 Suppl 1: 67–68.
16. Meurman JH. Infectious and dietary risk factors of oral cancer. *Oral Oncol* 2010; 46: 411–413.
17. Burket LW, Greenberg MS, Glick M, et al. *Burket's oral medicine*. 11th ed. Hamilton, Ont: BC Decker, 2008.
18. Oral Cavity and Oropharyngeal Cancer Prevention. *National Cancer Institute*, <https://www.cancer.gov/types/head-and-neck/patient/oral-prevention-pdq#section/all> (accessed 23 March 2018).
19. DeSantis CE, Lin CC, Mariotto AB, et al. Cancer treatment and survivorship statistics, 2014. *CA Cancer J Clin* 2014; 64: 252–271.
20. Onizawa K, Nishihara K, Yamagata K, et al. Factors associated with diagnostic delay of oral squamous cell carcinoma. *Oral Oncol* 2003; 39: 781–788.
21. Allen K, Ford PJ, Farah CS. Oral mucosal screening and referral attitudes of Australian oral health therapists and dental hygienists in Queensland. *Int J Dent Hyg* 2015; 13: 206–212.
22. Manrow RE, Beckwith M, Johnson LE. NCI's Physician Data Query (PDQ®) Cancer Information Summaries: History, Editorial Processes, Influence, and Reach. *J Cancer Educ* 2014; 29: 198–205.
23. Clinical Statistical Study of exfoliative Cytology Performed During Oral Cancer Screening in Chiba City in the past 11 years, [http://ir.tdc.ac.jp/irucaa/bitstream/10130/3988/1/8\\_33.pdf](http://ir.tdc.ac.jp/irucaa/bitstream/10130/3988/1/8_33.pdf) (accessed 17 May 2018).
24. Mupparapu M, Shanti RM. Evaluation and Staging of Oral Cancer. *Dent Clin North Am* 2018; 62: 47–58.
25. Street W. Cancer Facts & Figures 2018. 1930; 76.
26. Dionne Kalen R., Warnakulasuriya Saman, Binti Zain Rosnah, et al. Potentially malignant disorders of the oral cavity: Current practice and future directions in the clinic and laboratory. *Int J Cancer* 2014; 136: 503–515.
27. Warnakulasuriya S., Johnson Newell. W., Van Der Waal I. Nomenclature and classification of potentially malignant disorders of the oral mucosa. *J Oral Pathol Med* 2007; 36: 575–580.
28. Campbell H, Escudier MP, Brostoff J, et al. Dietary intervention for oral allergy syndrome as a treatment in orofacial granulomatosis: a new approach? *J Oral Pathol Med Off Publ Int Assoc Oral Pathol Am Acad Oral Pathol* 2013; 42: 517–522.
29. Sarode SC, Sarode GS, Tupkari JV. Oral potentially malignant disorders: precisising the definition. *Oral Oncol* 2012; 48: 759–760.
30. Waal I van der. Potentially malignant disorders of the oral and oropharyngeal mucosa; terminology, classification and present concepts of management. *Oral Oncol* 2009; 45: 317–323.
31. A OCFNT-. Management strategies for oral potentially malignant disorders. *Oral Cancer News*, <http://oralcancernews.org/wp/management-strategies-for-oral-potentially-malignant-disorders/> (accessed 17 May 2018).



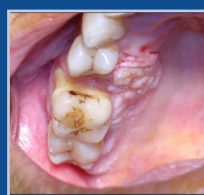## ANNEX 1

# Topography of lesions

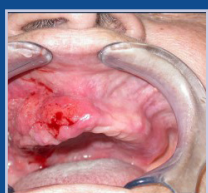Squamous cell carcinoma may appear anywhere in the oral mucosa, but the most common sites are the lateral borders of the tongue, the anterior floor of the mouth (more than 50% of all cases) , the gum-alveolar complex (particularly in the posterior mandibular region)<sup>26</sup>, the soft palate, and the labial mucosa.



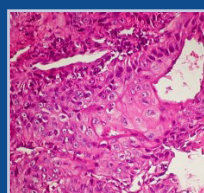
Idiopathic verrucous leucoplakia localized in the cheek



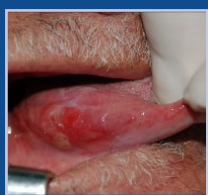Verrucous carcinoma in the palate



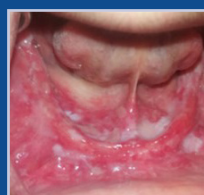SCC in the gum alveolar complex



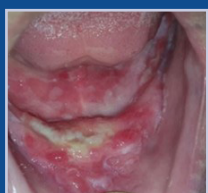Histopathologic view



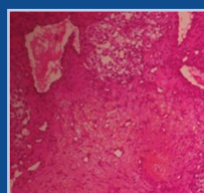
SCC in the lateral border of the tongue



Lichen planus in the floor of the mouth



Malign transformation of the lichen planus



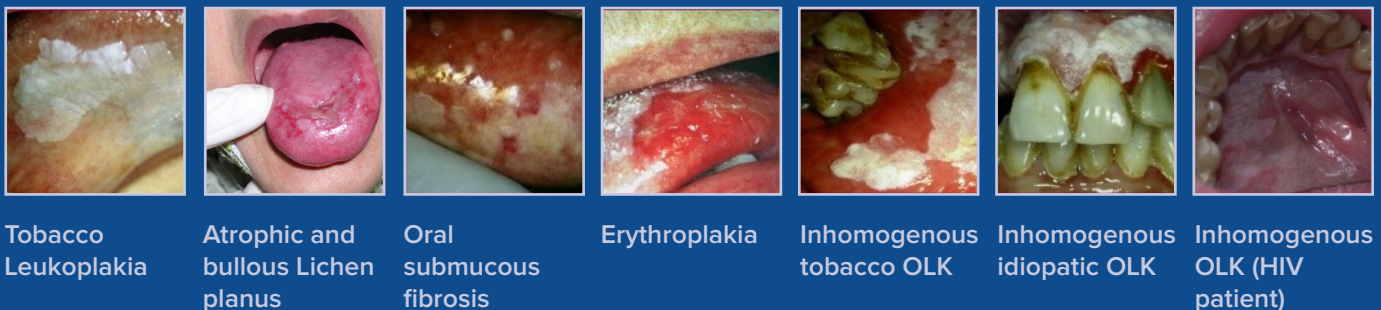
SCC well-differentiated, infiltrating and ulcerative

## ANNEX 2

# Oral potentially malignant disorders (OPMD)

OPMD are lesions and conditions that have an increased potential for malignant transformation and are risk indicators of future malignancies<sup>27,28</sup>. These disorders of varying aetiologies, most notably tobacco, are characterized by mutagen-associated, spontaneous or hereditary alterations or mutations in the genetic material of oral epithelial cells, with or without clinical and histomorphological alterations that may lead to oral squamous cell carcinoma transformation<sup>29</sup>. Although there is no scientific evidence that treatment of OPMDs prevents the development of oral cancer, managing the symptoms is necessary for the overall well-being of the patient<sup>30,31</sup>.

Early detection can reduce the malignant transformation of OPMD and improve oral cancer survival rate. The most common OPMDs are presented in the table below:



Management of OPMDs is critical to reduce symptoms and prevent the malignant transformation of these lesions. Depending on national professional regulations, OHPs may be involved in screening, diagnosing, referring, and/or managing patients with OPMDs and should be well-versed in the relevant standards of care. OHPs need to consider factors that may affect the therapeutic outcomes of OPMDs, including:

- ▶ Clinical features associated with an increased risk of malignant progression: lesion characteristics (larger size (>200 mm)), surface texture (smooth and indurated), inhomogeneous aspects (hyperkeratotic, thick), colour (red coloured or speckled, extent, unifocal, multifocal or diffuse pattern);
- ▶ Lesion location in the mouth, i.e. tongue, floor of mouth<sup>18</sup>;
- ▶ Patient risk factor assessment and detailed medical or systemic illness/cancer history and lesion histopathology.

## ANNEX 3

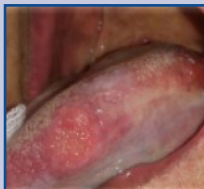# Clinical aspects of the squamous cell carcinoma

**Ulcerative form:** the ulceration is characterized by a raised external slope, separated from the inside with curved edges and a bottom containing necrotic debris. This ulceration has an indurated base. Ulceration is only the visible part of cancer.

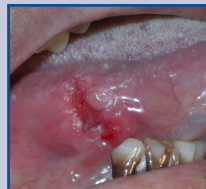**Budding or vegetative form:** tumour proliferation in bud.

**Ulcerobudding form:** necrosis of the top of the bud giving ulceration. There are also fissure and nodular forms.

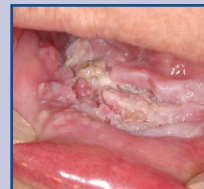The early lesions are often discreet and completely asymptomatic. In contrast, advanced lesions are typically indurated and may be associated with significant pain. At this stage, these carcinomas become easy to detect once they become symptomatic.



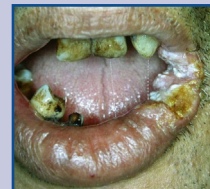Budding form



Ulcerative form



Ulcerobudding form



SCC in the lower lip



**FDI World Dental Federation**

Avenue Louis-Casaï 51 • 1216 Genève • Switzerland

+41 22 560 81 50 • [info@fdiworlddental.org](mailto:info@fdiworlddental.org) • [www.fdiworlddental.org](http://www.fdiworlddental.org)

**TEXT** Ihsane Ben Yahya  
Fani Anagnostou

**DESIGN** Gilberto D Lontro

©2018 FDI World Dental Federation